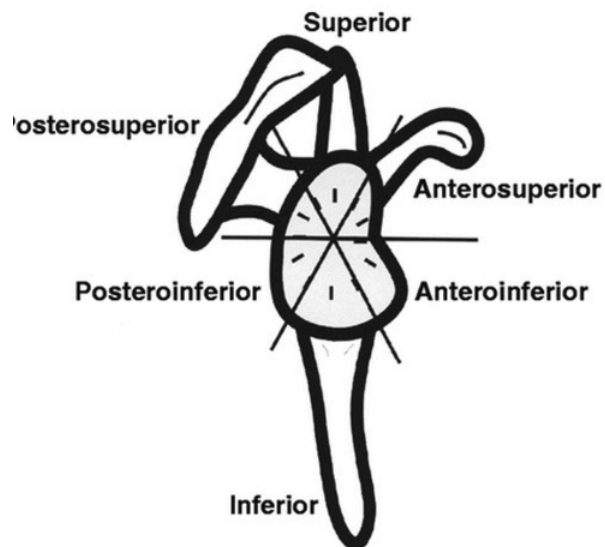
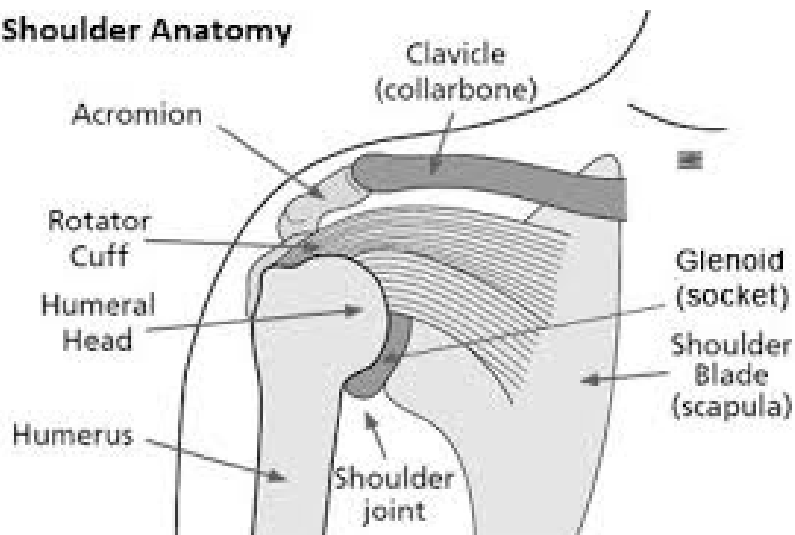


Shoulder Anatomy



Common Shoulder Diagnoses and Procedures

Arthroscopy:

- Using the camera in the joint with minimally invasive techniques

Shoulder Instability/Dislocation/Labrum tears:

- Anterior / Posterior Labrum Repair

Rotator Cuff Tear:

- Rotator Cuff Repair

Subacromial Impingement:

- Subacromial Decompression

Superior Labrum Tear (SLAP):

- Biceps Tenodesis

Acromioclavicular Joint Arthritis:

- Distal Clavicle Excision